


PRESENTING CLINICAL SIGNS

History: Recheck DMVD. Doing well. Sedated for exam with acepromazine and butorphanol.

DATE

11/15/21

ECHOCARDIOGRAPHIC FINDINGS

2D, M-mode, and Doppler study. This exam is compared to the one performed 5/12/21.

PERFORMED BY:

Dr. Brian Barnes

INTERPRETED BY

 Keith Blass, DVM,
 MS, DACVIM
 (Cardiology)

Left atrial size is normal. The mitral valve leaflets are mildly thickened, and a mild jet of eccentric mitral regurgitation is present. Left ventricular dimensions are normal, as is left ventricular systolic function. The aorta and aortic valve appear normal, though trace aortic insufficiency is present. Right atrial and right ventricular dimensions are normal. The tricuspid valve appears normal, though trace tricuspid regurgitation is present. TR velocity does not suggest the presence of pulmonary hypertension. The pulmonary artery and pulmonic valve appear normal, though trace pulmonic insufficiency is present. No pericardial effusion or cardiac masses are seen.

ECG during echo: Sinus arrhythmia

PATIENT

Vader Christmann

LA - 42.5 mm (prev. 41.2 mm)
 LVIDd - 41.2 mm (prev. 40.2 mm)
 LVIDs - 27.4 mm (prev. 24.7 mm)
 FS - 33.5% (prev. 38.5%)
 LVOT - 1.34 m/s (prev. 1.45 m/s)
 RVOT - 0.67 m/s (prev. 0.76 m/s)
 TR - 2.12 m/s (prev. 1.86 m/s)

SPECIES

Canine

ASSESSMENT/RECOMMENDATIONS

Degenerative mitral valve disease

BREED

Retriever

This examination is very similar to the one performed 6 months ago, and shows no real progression of Vader's mitral valve disease. As such, Vader's mitral valve disease still appears to be well-compensated, and his current risk for the development of clinical signs of cardiac dysfunction still appears to be relatively low.

No therapy is recommended at this stage of Vader's mitral valve disease.

SEX

A recheck echocardiogram is recommended in ~6 months to monitor for disease progression.

MN
AGE

11 y

WEIGHT

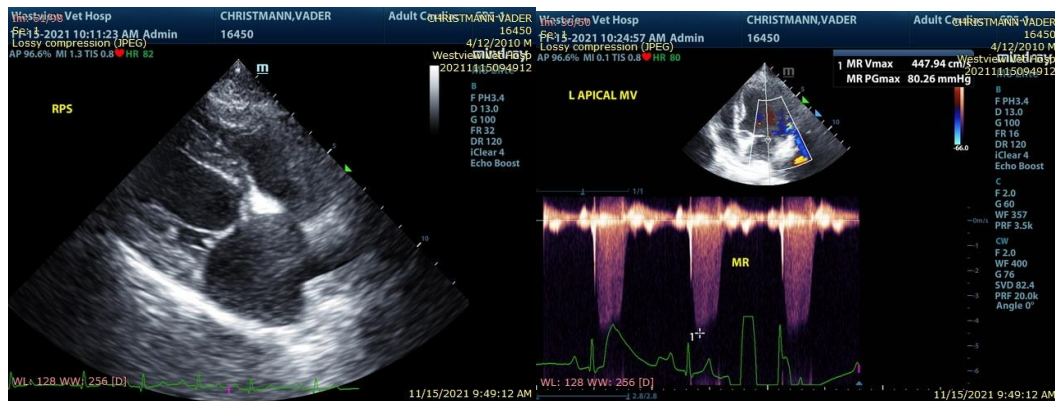
32.9 kg

HOSPITAL NAME

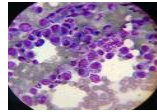
Westview VH

REFERRING VET

Dr. Barnes



The information and recommendations provided are based on the images presented by the referring veterinarian. No evaluation can be communicated regarding pathology that was not



visible in the image/video clips provided.

DATE

11/15/21

Thank you for this referral. If the clinical or image interpretation does not parallel your findings or if I can be of any further assistance please contact me.

PERFORMED BY:

Keith Blass, DVM, MS, DACVIM (Cardiology)
KeithBlass@gmail.com
631-804-5754

Dr. Brian Barnes

INTERPRETED BY

Keith Blass, DVM,
MS, DACVIM
(Cardiology)

PATIENT

Vader Christmann

SPECIES

Canine

BREED

Retriever

SEX

MN

AGE

11 y

WEIGHT

32.9 kg

HOSPITAL NAME

Westview VH

REFERRING VET

Dr. Barnes